

DST-106 Conjunctivitis: Pediatric

DEFINITION

Inflammation and erythema of the conjunctiva, caused by hyperemia of tortuous superficial vessels secondary to infection (viral or bacterial) or allergic reaction (histamine).

Nurses with Remote Practice Certified Practice designation (RN(C)s) are able to treat children with conjunctivitis who are **6 months of age and older**.

POTENTIAL CAUSES

Conjunctivitis is usually viral or bacterial

The allergic form is more common when accompanied by other allergic symptoms such as rhinitis. Wearing contact lenses

Foreign body, acid or alkali burn to eye

Other causes include preseptal or orbital cellulitis, corneal injury, uveitis and glaucoma all of which are referred to a physician or nurse practitioner

Bacterial Pathogens

- Chlamydia
- *Neisseria gonorrhoea*
- *Haemophilus influenza* (non-typable)
- Moraxella Species
- *Pseudomonas Aeruginosa*¹
- *Staphylococcus aureus* (more common in adults)
- *Streptococcus pneumonia*

Note: In youth, gonococcal or chlamydial infection should be considered if the history is supportive of this diagnosis and the adolescent is sexually active.

Viral Pathogens

- Adenovirus (most common virus in children)
- Coxsackie virus
- Enterovirus 70
- Epstein-Barr virus herpes zoster virus (less common)
- Measles and rubella viruses
- Allergic Response Environmental exposure
- Seasonal pollens

PREDISPOSING RISK FACTORS

Contact with another person who has conjunctivitis, other atopic (allergic) conditions and exposure to allergens or exposure to a sexually transmitted infection (STI).

TYPICAL FINDINGS OF CONJUNCTIVITIS

Physical Assessment

Examination should be very brief in the case of a chemical injury to the eye as irrigation of the eye is priority and should begin immediately. A topical anesthetic, e.g. tetracaine, may be used if the examination is uncomfortable for the patient.

Children with mild viral or superficial bacterial conjunctivitis do not usually have significant systemic symptoms. However, assess:

- Vital signs and pain assessment
- Perform a general assessment if the client appears systemically ill (i.e., fever)
- Weigh (for medication calculations i.e. acetaminophen, ibuprofen)
- Visual acuity if old enough
- Assess both eyes for symmetry
- Assess eyelids and orbits for crusting, edema, ulceration, nodules, discoloration, inversion of eyelashes, papillary reaction
- Palpate the bony orbit, eyebrows, lacrimal apparatus and pre-auricular lymph nodes for tenderness, swelling or masses
- Assess the conjunctiva for erythema, edema, discharge, foreign bodies, phlyctenules (white granules on corneal edge surrounded by erythema) or other abnormalities
- Note the pattern of injection such as conjunctival haemorrhage or ciliary flush
- Pupils equal, round, reactive to light and accommodation (PERRLA)
- Examine the anterior segment of the globe with a small penlight
- Assess ocular mobility by checking range of movement. Use a fluorescein stain to assess for corneal abrasion or ulcers if history or physical findings suggest corneal abrasion. Corneal cells that are damaged or lost will stain green; cobalt blue light allows easier visualization of the abrasion.

Carefully document all evidence of external trauma

Bacterial Infection

History

- Eye(s) red, often unilateral initially, may spread to both eyes
- Burning, gritty sensation or foreign body sensation in eyes
- Thick, purulent discharge with crusting in morning
- Complicating bacterial infections, such as otitis media, may be evident
- Recent contact with others with similar symptoms
- Recent sexual activity and possible STI

Common Findings

- Conjunctiva erythematous (unilateral or bilateral)
- Chemosis (swelling of conjunctiva) if severe
- Purulent discharge
- PERRLA
- Visual acuity normal
- Pre-auricular nodes palpable in *Neisseria gonorrhoea* and Chlamydia and MRSA

Viral Infection

History

- Acute onset of conjunctival injection¹ commonly preceded by a viral upper respiratory tract infection
- May begin unilateral, but often bilateral within 24-48 hours
- No pain, mild to stabbing pain, possibly gritty sensation or mild itching.
- Tearing or mucoid discharge
- Systemic symptoms may be present (e.g., sneezing, runny nose, sore throat, preauricular lymphadenopathy)
- Recent contact with others with similar symptoms

Common Findings

- Conjunctiva erythematous (unilateral or bilateral)
- Chemosis (swelling of conjunctiva) if severe
- Watery or mucoid discharge
- PERRLA Visual acuity - normal
- Enlarged, tender preauricular nodes
- Lasts 1-4 days; infectious for up to 2 weeks
- Dendritic keratitis on fluorescein staining with herpes simplex virus

Note: clinical factors cannot reliably differentiate viral from bacterial causes

Allergic Response

History

- Seasonal, known or environmental allergies, allergic rhinitis
- Eczema, asthma, urticaria
- Bilateral watery, red, itchy eyes, without purulent drainage

Common Findings

- Sequential bilateral red eyes
- Watery discharge and inflammation around the eye and eyelids, which can produce dramatic conjunctival swelling (chemosis) and lid oedema, to the extent that the eye is swollen shut
- A feeling of grittiness or stabbing pain
- May have rhinorrhea or other respiratory symptoms
- Crusting of the lashes overnight can sometimes be confused for a purulent discharge
- Enlarged, tender preauricular lymph nodes are often present, and are a useful feature to assist diagnosis
- PERRLA
- Visual acuity - normal

Diagnostic Tests

- Specimens should be obtained for culture and smear if inflammation is severe, in chronic or recurrent infections, with atypical conjunctival reactions, and with failure to respond to treatment⁴
- Swab for gonorrhoea or chlamydia

MANAGEMENT AND INTERVENTION

Note: Review Appendix 1: Algorithm for Diagnosing the Cause of Red eye

Goals of Treatment

- Relieve symptoms and resolution of infection
- Rule out more serious infections (e.g., uveitis)
- Prevent complications
- Prevent spread of infection to others

Non-pharmacologic Interventions

- Apply warm or cool compresses to eyes, lids and lashes qid for 15 minutes
- Clean eyelids gently of discharge with warm water and a disposable wipe such as a cotton swab or tissue
- Avoid rubbing the eye(s)
- Public health measures that support good hygiene (i.e., frequent hand-washing, use of separate clean face cloth and towels).

Pharmacological Interventions

Note:

- Many pediatric drug doses are calculated by weight.
- Topical eye drops and eye ointments may be used as listed below.
- Pediatric doses should not exceed recommended adult doses.
- Never use steroid or steroid-and-antibiotic combination eye drops, because the infection may progress or a corneal ulcer may rapidly form and cause perforation

Bacterial Infection

Acute conjunctivitis is frequently self-limiting, and antibiotics are of limited benefit. It may be appropriate to hold antibiotics for two or three days and start therapy if no improvement or the condition worsens.

- Topical antibiotic eye drop or ointment treatment options for children greater than 1 year of age:
 - gramicidin- polymyxin B ophthalmic solution, 1 drop, every 3 to 4 hours, for 5-7 days, or
 - sulfacetamide 10% ophthalmic solution, 1 to 2 drops, every 2 to 3 hours, for 5-7 days, or
 - bacitracin-polymyxin B eye ointment, 1 cm ribbon, QID, for 5-7 days, or
 - erythromycin 0.5% eye ointment, 1 cm ribbon, QID, for 5-7 days
 - moxifloxacin 0.5% drops, 1 drop TID for 7 days (for treatment of pseudomonas.)

Note: eye ointment may be preferred for younger children and infants.

An antibiotic eye ointment may be used at bedtime in addition to the daytime antibiotic eye drops prn:

- erythromycin 0.5% eye ointment for 5-7 nights at bedtime, or
- bacitracin-polymyxin ointment for 5-7 nights at bedtime.

Viral Infection

- Artificial tears or saline washes often provide excellent symptomatic relief (antibiotics are not indicated)
- artificial tears, 1 or 2 drops prn

Allergic Response

- Artificial tears or saline washes and cool compresses often provide excellent symptomatic relief (antibiotics are not indicated)
- artificial tears, 1 or 2 drops prn

Oral antihistamines may be tried if symptoms are severe. Most common side effects are drowsiness, dry mouth, and fatigue:

- cetirizine (syrup 5 mg/5 mL), Children 2-6 years of age, 5 mL (1 teaspoon) once daily. For twice daily dosing, 2.5 mL (one-half teaspoon) in the morning and 2.5 mL (one-half teaspoon) of syrup in the evening. Children 6-12 years of age, 10 mL (2 teaspoons) of syrup once daily. For twice daily dosing, 5 mL (one teaspoon) in the morning and 5 mL (one teaspoon) in the evening.

OR

- desloratadine (syrup 0.5 mg/mL), Children 2 Through 5 Years of Age, 2.5 mL (1.25 mg) once a day, regardless of mealtime. Children 6 Through 11 Years of Age 5 mL (2.5 mg) once a day, regardless of mealtime. 12 years of age or older: 5 mg po daily

OR

- loratidine: (Oral Solution 1 mg/mL). Children 10 years of age and over (body weight greater than 30 kg): 10 mL (two teaspoonfuls) once daily. Children 2 through 9 years of age (body weight less than or equal to 30 kg): 5 mL (one teaspoonful) once daily.
- CLARITIN KIDS should not be administered to children between 2 and 12 years of age for longer than 14 days, unless recommended by a physician.
 - For children 4 years and older, topical antihistamine eye drops are recommended if symptoms are not controlled by oral antihistamines or oral antihistamines cannot be tolerated:
- cromolyn Na 4% eye drops, 1-2 drops every 4-6 hrs.

Pregnant and Breastfeeding Youth (dosing as above)

- Erythromycin eye ointment, polymyxin B gramicidin eye drops, bacitracin-polymyxin eye ointment, artificial tears, cromolyn Na, cetirizine and loratadine may be used as listed above.
- ONLY USE sulfacetamide if clearly needed.
- DO NOT USE desloratadine.

POTENTIAL COMPLICATIONS

- Spread of infection to other eye structures
- Spread of infection to others

CAREGIVER EDUCATION AND DISCHARGE INFORMATION

Provide advice regarding:

- the condition, timeline of treatment and expected course of disease process (dose, frequency, and instillation)
- avoid using eye cosmetics during acute phase
- contact lenses wearers- discontinue wearing until condition is resolved
- allergic form: recommend that child avoid going outside when pollen count is high. Protective glasses can be worn to prevent pollen from entering the eyes.

Provide infection control education regarding:

- preventing the spread of infection and hygiene of hands and eyes. Wash hands often.
- preventing contamination of the medication tube or bottle
- not sharing of eye drops or ointments, eye cosmetics, towels or face cloth
- discarding contaminated eye cosmetics which may harbor bacteria and cause recurrent infection.
- For infectious forms, recommend school or day care restrictions until improved or there is no further discharge.

INSTRUCT CLIENT/CARE GIVER TO WASH PILLOWCASES, SHEETS, LINENS OFTEN. IN HOT WATER. MONITORING AND FOLLOW-UP

- Clients with moderate or severe symptoms should be seen for follow-up at 24 and 48 hours.
- Follow up appropriately in 2 or 3 days or sooner if symptoms do not improve.

CONSULTATION AND/OR REFERRAL

Consult or referral as indicated under the following circumstances:

- child is less than 6 months of age,
- if condition deteriorates, if symptoms persist despite treatment, or if symptoms recur,
- the diagnosis is in doubt and significant ocular infections like uveitis, herpes and gonorrhea cannot be ruled out,
- there is associated trauma (i.e., blow to eye and or penetrating eye injury (high potential for referral),
- serious chemical eye injury (high potential for referral),
- visual acuity is decreased or deficit in colour vision,
- moderate or severe pain
- atypical ocular exam
- the condition recurs frequently.

DOCUMENTATION

- As per agency policy

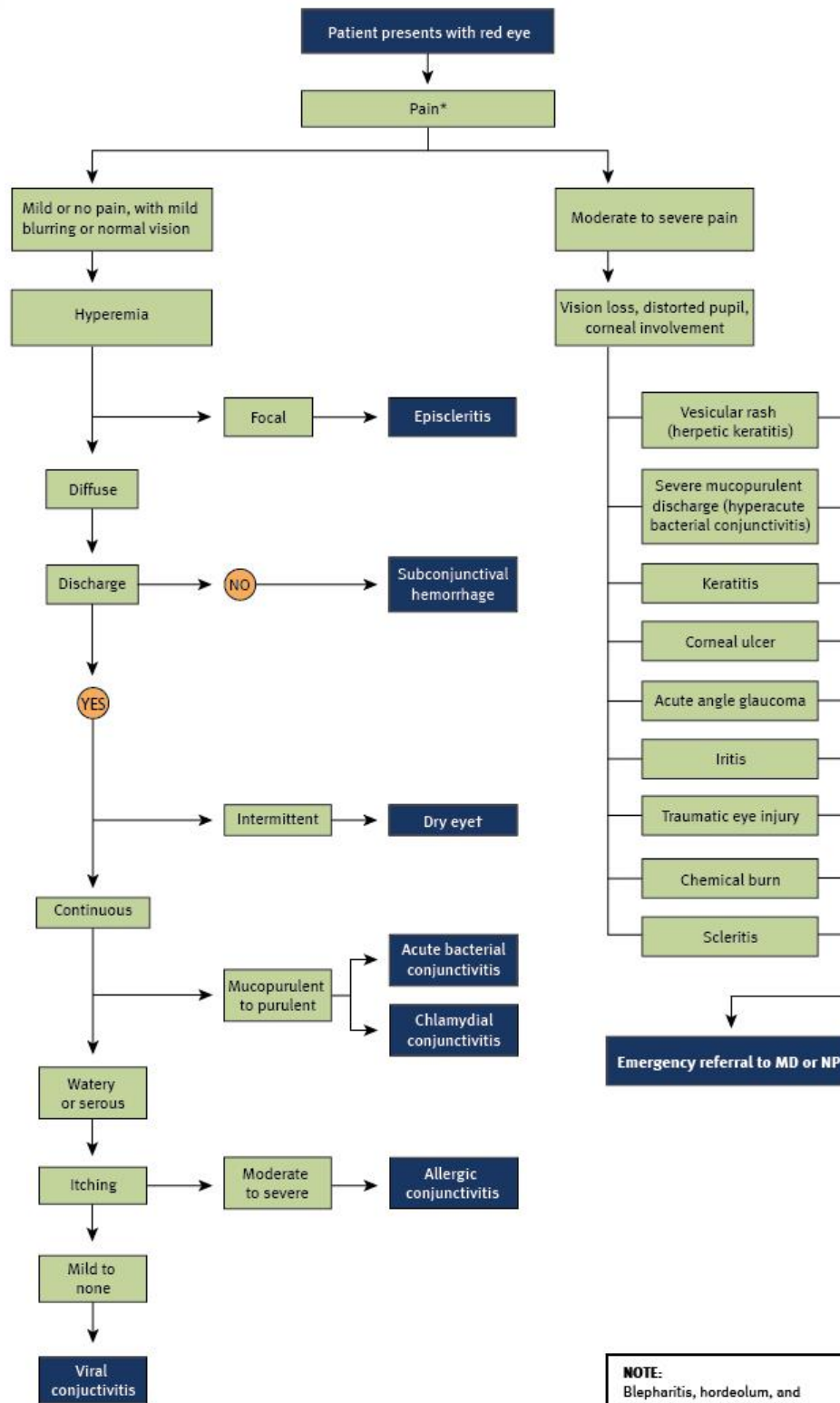
REFERENCES

More recent editions of any of the items in the Reference List may have been published since this DST was published. If you have a newer version, please use it.

- Anti-Infective Review Panel. (2012). *Anti-infective guidelines for community-acquired infections*. Toronto, ON: MUMS Guideline Clearinghouse.
- Azari, A. A., & Barney, N. P. (2013). Conjunctivitis: A systematic review of diagnosis and treatment. *JAMA: Journal of the American Medical Association*, *310*(16), 1721-1729.
- Blondel-Hill, E., & Fryters, S. (2012). *Bugs and drugs: An antimicrobial infectious diseases reference*. Edmonton, AB: Alberta Health Services
- Canadian Pharmacists Association. (2014). *Therapeutic Choices* (7th ed.). Ottawa, ON: Author
- Canadian Pharmacists Association. (2014). *Therapeutic choices for minor ailments*. Ottawa, ON: Author.
- Cash, J. C., & Glass, C. A. (Eds.). (2014). *Family practice guidelines* (3rd ed.). New York, NY: Springer.
- Council of Canadian Academics. *Improving Medicines for Children in Canada*. Ottawa: 2014.
- Cronau, H., Kankanala, R. R., & Mauger, T. (2010). [Diagnosis and management of red eye in primary care](#). *American Family Physician*, *81*(2), 137-144.
- DynaMed. (2015, July 31). *Allergic conjunctivitis*.
- DynaMed. (2015, June 9). *Infectious conjunctivitis*.
- Epling, J. (2010). [Bacterial conjunctivitis](#). *American Family Physician*, *82*(6), 665-666.
- Everitt, H.A., Little, P.S., & Smith P.W. (2006). A randomized controlled trial of management strategies for acute infective conjunctivitis in general practice. *British Journal of Medicine*, *333*(7563): 321.
- Esau, R. (Ed.). (2012). *British Columbia's Children's Hospital pediatric drug dosage guidelines* (6th ed.). Vancouver, BC: Children's & Women's Health Centre of B.C.
- Friedlaender, M. H. (2011). Ocular allergy. *Current Opinion in Allergy and Clinical Immunology*, *11*(5), 477-482.
- Gold, R.S. (2011). Treatment of bacterial conjunctivitis in children. *Pediatric Annals*, *40*(2), 95-105.
- Golde, K. T., & Gardiner, M. F. (2011). Bacterial conjunctivitis in children: A current review of pathogens and treatment. *International Ophthalmology Clinics*, *51*(4), 85-92.
- Infective conjunctivitis. (2011, September 5). *Independent Nurse*, 29-30.
- Jacobs, D. S. (2015). [Conjunctivitis](#). *UptoDate*.
- Jefferis, J., Perera, R., Everitt, H., van Weert, H., Rietveld, R., Glasziou, P., & Rose, P. (2011). [Acute infective conjunctivitis in primary care: Who needs antibiotics? An individual patient data meta-analysis](#). *British Journal of General Practice*, *61*(590), e542-e548.
- Karpecki, P., Paterno, M., & Comstock, T. (2010). Limitations of current antibiotics for the treatment of bacterial conjunctivitis. *Optometry and Vision Science: Official publication of the American Academy of Optometry*, *87*(11), 908-919.

- Klostranec, J. M., & Kolin, D. L. (2012). *The Toronto notes 2012: Comprehensive medical reference and review for the Medical Council of Canada Qualifying Exam Part 1 and the United States Medical Licensing Exam Step 2* (28th ed.). Toronto, ON: Toronto Notes for Medical Students.
- La Roche, R., Hamilton J. [Vision screening in infants, children and youth](#). *Paediatr Child Heal.* 2009;14(4):246-248. Retrieved from. La Rosa, M., Lionetti, E.,
- Reibaldi, M., Russo, A., Longo, A., Leonardi, S., & ... Reibaldi, A. (2013, March). [Allergic conjunctivitis: A comprehensive review of the literature](#). *Italian Journal of Pediatrics, 39*.
- Lexicomp Online. Polymxcin, Sulfacetamide etc.. Retrieved from <http://online.lexi.com>
- Mitchell L, Grimmer P. [Complications & treatment of a red eye](#). *Bpj.* 2013;54(54):8-21.
- O'Brien, T. P. (2013). Allergic conjunctivitis: An update on diagnosis and management. *Current Opinion in Allergy & Clinical Immunology, 13*(5), 543-549.
- O'Brien TP, Jeng BH, McDonald M, Raizman MB. Acute conjunctivitis: truth and misconceptions. *Curr Med Res Opin.* 2009;25(8):1953-1961.
- Pichichero, M. (2011). Bacterial conjunctivitis in children: Antibacterial treatment options in an era of increasing drug resistance. *Clinical Pediatrics, 50*(1), 7-13.
- Rosario, N., & Bielory, L. (2011). Epidemiology of allergic conjunctivitis. *Current Opinion in Allergy & Clinical Immunology, 11*(5), 471-476.
- Seth, D., & Khan, F. I. (2011). Causes and management of red eye in pediatric ophthalmology. *Current Allergy and Asthma Reports, 11*(3), 212-219.
- Sheikh, A., Hurwitz, B., van Schayck, C. P., McLean, S., & Nurmatov, U. (2012). Antibiotics versus placebo for acute bacterial conjunctivitis (review). *Cochrane Database of Systematic Reviews, (9)*.
- Shin H, Price K, Albert L, Dodick J, Park L, Dominguez-bello G. Changes in the eye microbiota associated with contact lens wearing. 2016;7(2):1-6. doi:10.1128/mBio.00198-16.
- Spering, K. A. (2011). Therapeutic strategies for bacterial conjunctivitis. *Clinical Advisor for Nurse Practitioners, 14*(8), 31-40.
- Thanathanee, O., & O'Brien T. (2011). Conjunctivitis: Systematic approach to diagnosis and therapy. *Current Infectious Disease Reports, 13*(2), 141-148.
- Visscher, K. L., Hutnik, C. M. L., & Thomas, M. (2009). [Evidence-based treatment of acute infective conjunctivitis: Breaking the cycle of antibiotic prescribing](#). *Canadian Family Physician, 55*(11), 1071-1075.

APPENDIX 1: ALGORITHM FOR DIAGNOSING THE CAUSE OF RED EYE



Cronau, Kankanala, & Mauger (2010)

Adapted with permission from *Diagnosis and Management of Red Eye in Primary Care*, January 15, 2010, Vol 81, No 2, *American Family Physician* Copyright © 2010 American Academy of Family Physicians. All Rights Reserved.

NOTE:
Blepharitis, hordeolum, and chalazion are associated with localized red, swollen, tender eyelid; other symptoms are rare.

* -- patients with corneal abrasion may present with severe pain, but treated by a primary care physician.

† -- Paradoxical tearing of the eye.